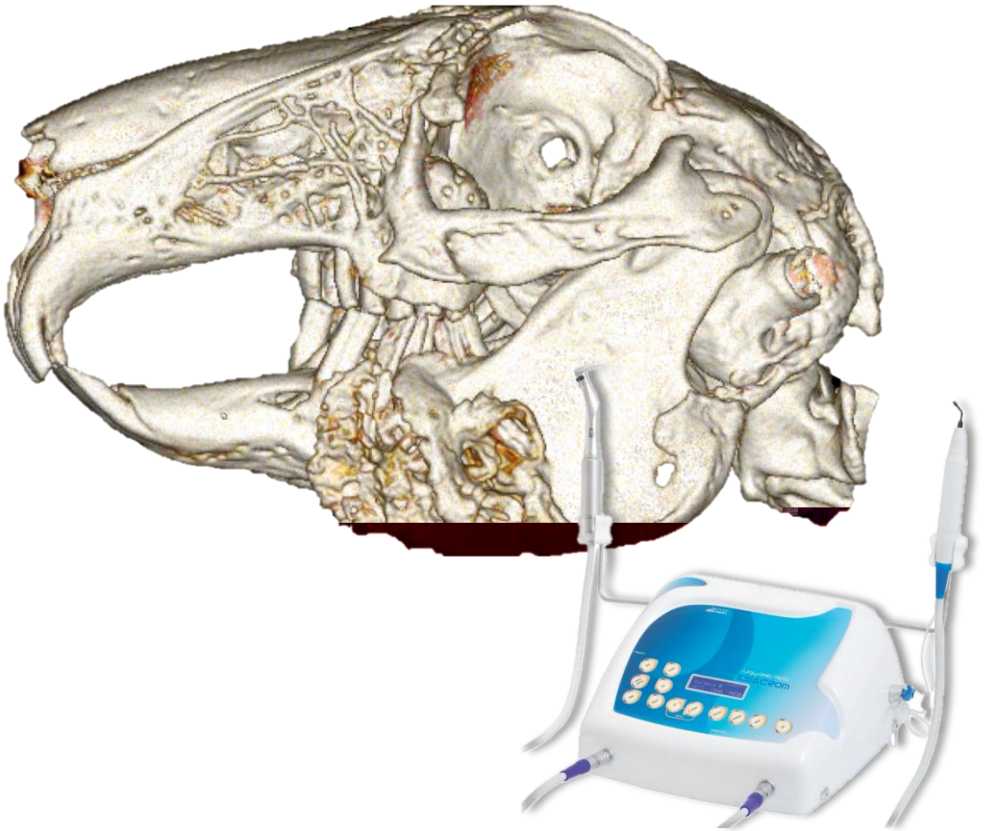


ESACROM R&D DEPT.

PRESENTS

MINIMALLY INVASIVE MAXILLOFACIAL SURGERY IN THE RABBIT

By Dr. Francesco Paesano



05-03-2024

INTRODUCTION

The rabbit is the most common pet in our homes after dog and cat and therefore the demand for cutting-edge medical and surgical care is increasing.

Due to its physio-pathology it has a high incidence of **dental pathologies**, which often culminate in abscess injuries and if not treated properly may hesitate in death. Other very frequent diseases that affect the region of our interest are chronic rhinitis and otitis media.

The correct surgical treatment of these pathologies with formation of purulent material always passes from the removal of the necrotic tissue, pus and of course of the infected dental elements through **osteotomies** . However the small size and fragility of rabbit bones make these procedures a non-trivial challenge for the surgical.

For years now, hard tissue surgery in human medicine has seen the advent of **technological innovations** such as **Piezo surgery**, which has greatly changed the way we approach all simple and complex procedures, thus providing new tools and new possibilities to successfully address them.

The numerous **advantages** of this technology make it the ideal tool in the field of maxillofacial rabbit surgery:

- **Selective cutting** of mineralized tissues without damaging the soft (vessels, nerves);
- **Intraoperative control** and **efficacy** inversely proportional to the **force** applied by the operator;
- Ability of ultrasound **to separate tissues with different consistency and density** (ie the tooth from the bone);
- **Reduced iatrogenic trauma** and **respectful of tissue healing** (no bone necrosis on the cutting line as opposed to traditional rotating instruments);

POST-OPERATIVE FUNCTION

The **piezoelectric technology** can be used with special programs also to **medicate in the post operative** all these infected lesions better than any other technique. Possible through ultrasonic debridement, which allows you to selectively remove necrotic tissue without damaging healthy tissues, has antibacterial action and does not require general anesthesia.

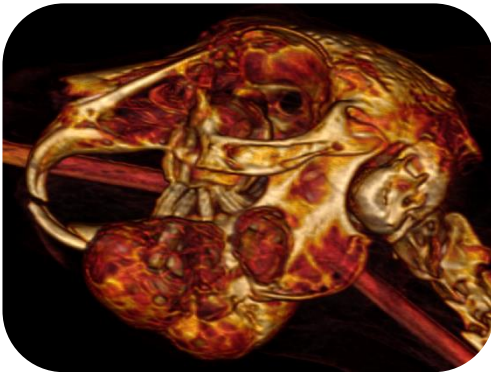
- 1 Selective system that does not damage healthy tissues;
- 2 Deep cleansing and cleaning;
- 3 Antibacterial effect of bactericidal cavitation;
- 4 Reduction of debridement time and number of treatments;
- 5 Pain reduction and management;
- 6 Reduction of exudate;

MULTIPLE ABSCESSSES AND MANDIBULAR OSTEOMYELITIS

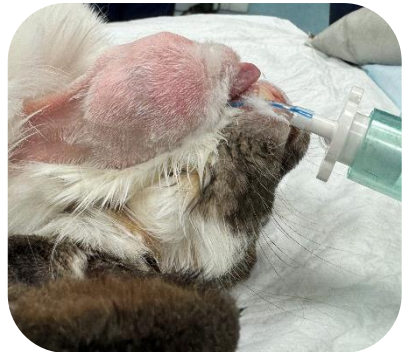The treatment of dental facial abscesses is complex because it is always associated with osteomyelitis and very dense caseous pus.

Often, subjects with acquired dental disease have more than one pathological dental element, and when abscess lesions develop these can also involve all the dental elements of a quadrant.

The use of **Piezosurgery** allows to **remove the necrotic bone** preserving the healthy one, to **expose the dental elements** and to **dislocate them without applying force** so as to greatly **reduce the possibility of iatrogenic fractures** (complication with poor prognosis).



Severe multiple abscess injury with bone expansion and osteolysis involving all the horizontal branch of the left jaw



Appearance of the patient in the dorsal decubitus in preparation for the surgery

①



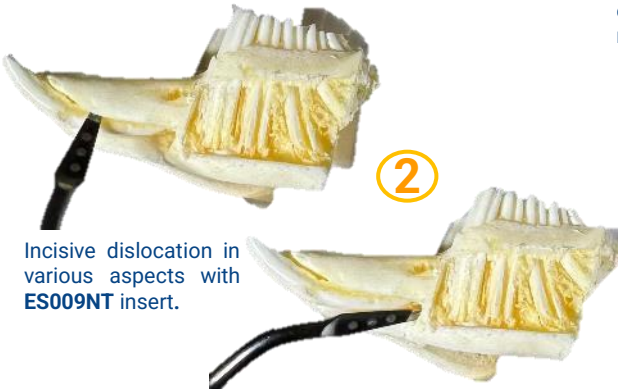
Alveoloplastic with **ES010T** insert to expose incisor.

③



Incisive mobilization with **ES012ET** insert.

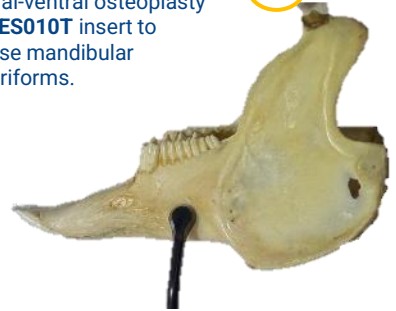②



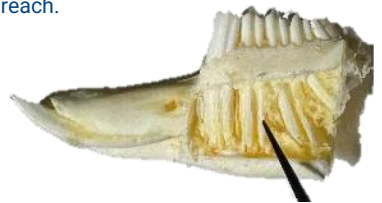
Incisive dislocation in various aspects with **ES009NT** insert.

④

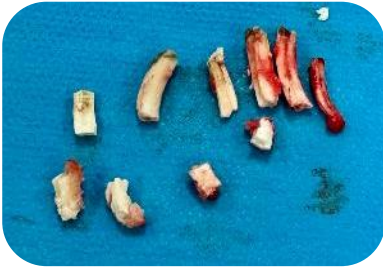
Lateral-ventral osteoplasty with **ES010T** insert to expose mandibular molariforms.



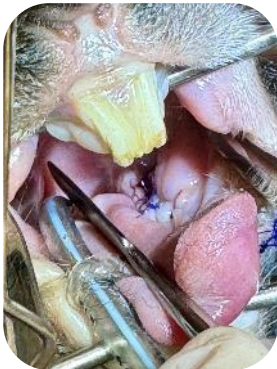⑤



Molariform dislocation and mobilization with **ES012ET** insert. We recommend sectioning the dental elements with **ES007W1T** insert to facilitate extraction through surgical breach.

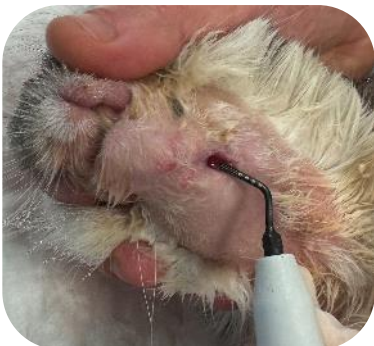

The 5 extracted mandibular molariforms, mandibular incisor and necrotic bone removed by osteotomy with **ES007W1T** insert.



Mucogingival suture
intraoral.

POST-OPERATIVE FUNCTION



For post-operative dressings, **ultrasonic debridement** with **ES020XT** insert is performed without sedation.

This technique **halves the healing time**.

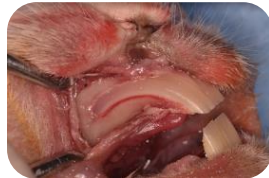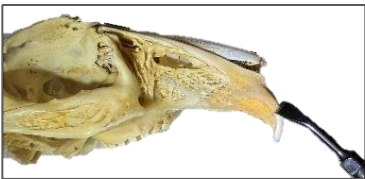INCLUDING MAXILLARY INCISOR EXTRACTION

In the event of a **traumatic or iatrogenic dental fracture** during the extraction procedure of the incisors, **surgical avulsion** of the spare crown can be performed with the aid of **piezo surgery**.

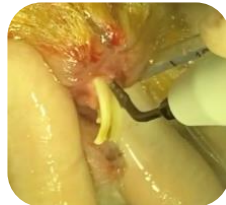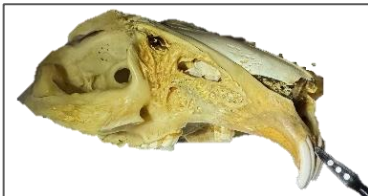Once we have exposed the lateral wall of the incisor alveolar bone, we go to perform osteoplasty until we visualize the dental element.

Then, as already seen for the mandibular incisor, we go to dislocate the spare crown with the insert **ES009NT** and to avulsionarlo with insert **ES012ET**.

This minimally invasive technique is very well tolerated by the patient, because it is more respectful of the tissues than traditional techniques.

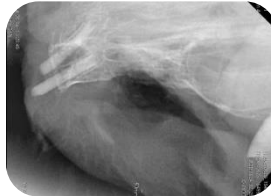
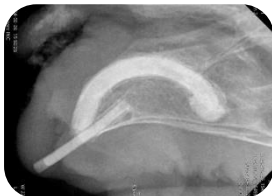
Following the skeletonization of the lateral incisor alveolar bone, osteoplasty is performed with **ES007ST** and **ES010T** inserts.



It can facilitate the dislocation of the tooth by using **ES009NT** insert both in the apical direction and in all aspects of the reserve crown once exposed by osteoplasty.

**PRE
EXTRACTION**
RX granted by Dr.
Ermano Esposito



**POST
EXTRACTION**



Video of the procedure.
Scan the QR code!

RETROBULBAR ABSCESS AND EN BLOC EXTRACTION OF MAXILLARY MOLARIFORMS

For the treatment of maxillary dental abscesses a new technique has been described with a **90% success rate without complications** (V.Jekl. Advances cases of full unilateral maxillary premolar and molar extraction in rabbits. Proceeding 30th EVDF, Krakow 2023).

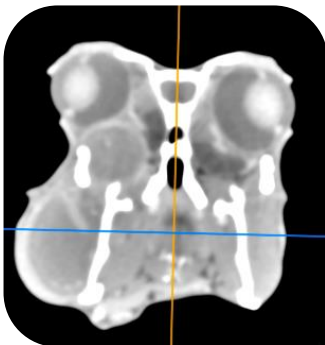
This procedure consists in extraoral extraction of all premolars and molars through **obstetomy** of zygomatic arch and facial tuberosity, and removal of the lateral wall of the alveolar bubble.

This approach allows the **seamless suture of the buccal gum with the palatal mucosa**, preventing food from accumulating in the wound and delaying healing.

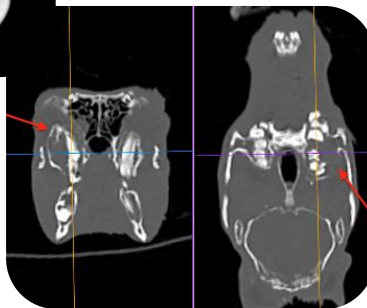
Performing this complex procedure with piezo surgery allows you to work safely avoiding damaging the retrobulbar venous sinus, the infraorbital neurovascular cord and the angular vein of the eye; in fact the Piezo allows to work in limited fields with poor visibility without damaging the soft tissues, as opposed to rotating instruments.

The **vibrations of the insert** allow you to remove the dental helmets without applying force, so as to speed up the procedure and not risk iatrogenic fractures.

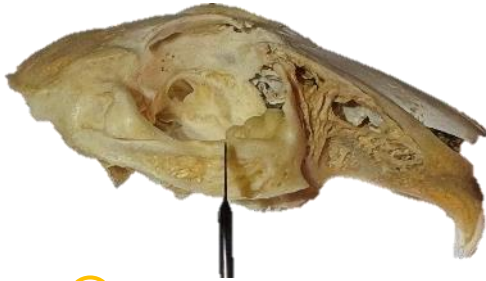In order to facilitate extraction through the extraoral breach, it is also possible to dissect the molariforms with **ES007W1T** osteotomy insert.



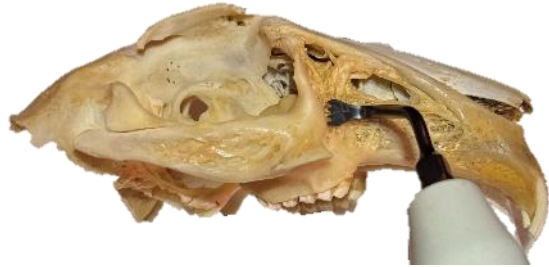Retrobulbar maxillary abscesses



Video of the procedure.
Scan the QR code!



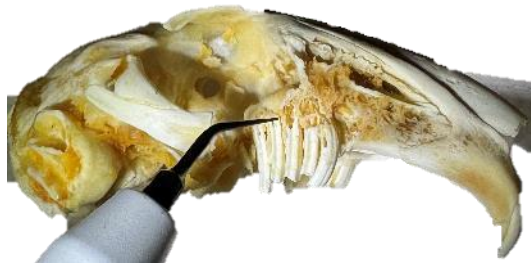① Osteotomy zygomatic arch
Insert **ES007W1T**



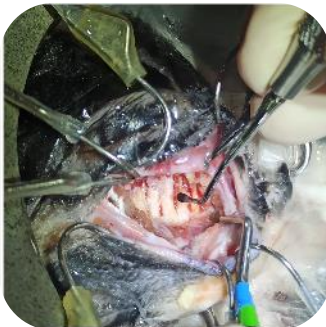
② Osteotomy tuberosity of the face
Insert **ES007LT/ES007RT**



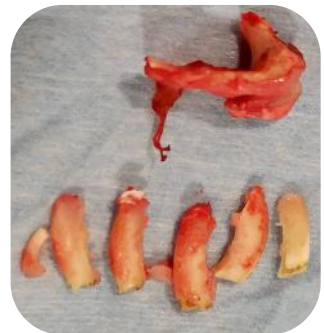③ Osteoplastic patere lateral alveolar bubble
Insert **ES010T**



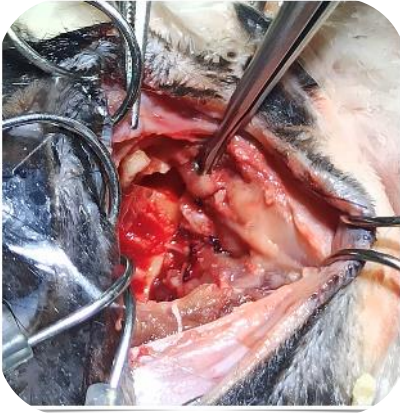
④ Molariform luxation with insert
Insert **ES012T**



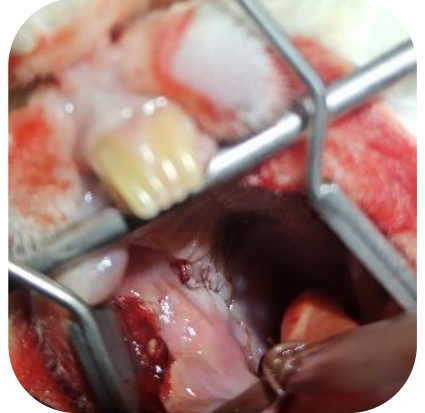Intraoperative postalveolotomy and extraoral pre-experiments



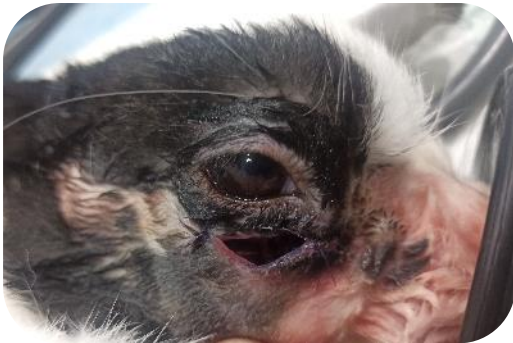The 6 molariforms maxillary post extraction, zygomatic arch with tuberosus facial post osteotomy



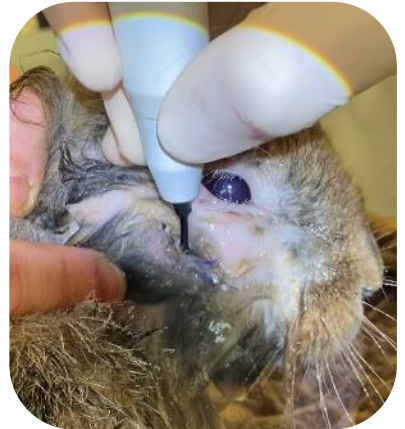Extraoral suture after extractions



Intraoral vision of the extraoral mucogingival suture



Appearance of Marsupialization at the end of surgery



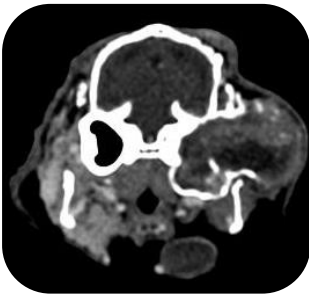For post-operative dressings, ultrasonic debridement with diamond insert without sedation is performed. This technique halves the healing time.

OBSTETOMY TYMPANIC BLISTER FOR OTITIS MEDIA

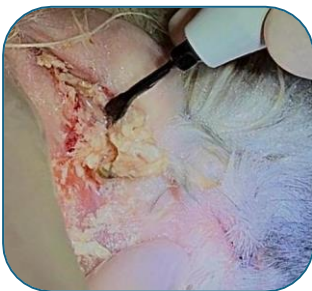The average otitis, consequence of the external otitis, have a high incidence in particular in the Aries breed according to the different anatomy of the auditory canal. If left untreated, otitis media causes expansion and bone lysis, leading to: the impediment of normal movement of the vetical branch of the jaw, neurological deficits such as horner syndrome and vestibular sindorme and finally meningo-encephalitis.

Surgical treatment is the only viable option, especially in advanced cases. The latter consists of the removal of the lateral wall of the ear canal and the osteotomy of the tympanic bubble so that puruling material, necrotic bone and the abscess epithelium can be removed. However, the anatomical region is surrounded by important neurovascular structures, such as the facial nerve, arteries and auricular veins caudal and rostral.

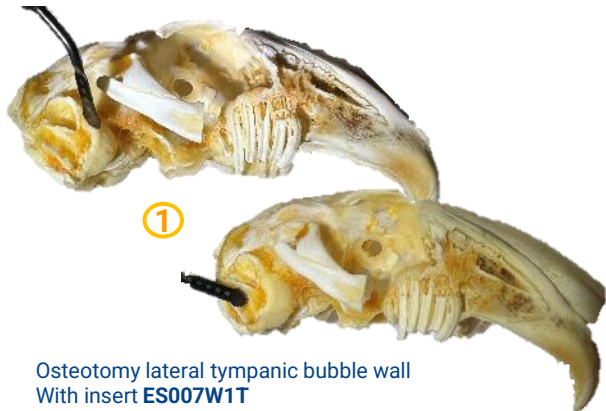
The use of **piezo surgery** makes this surgery safe and much more efficient than traditional techniques.



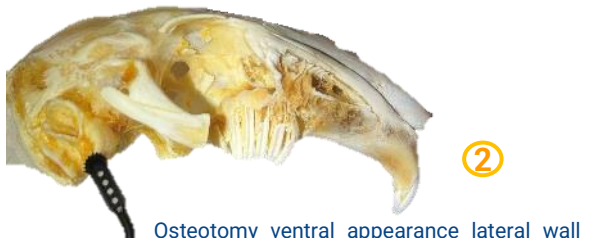Severe otitis media with massive bone expansion and lysis tympanic bubble



PRE. Procedure: debridement to remove necrotic tissue with **ES001T** insert



Osteotomy lateral tympanic bubble wall
With insert **ES007W1T**



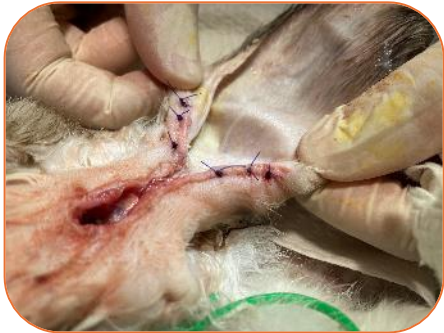Osteotomy ventral appearance lateral wall
Alveolar bubble

HEALING

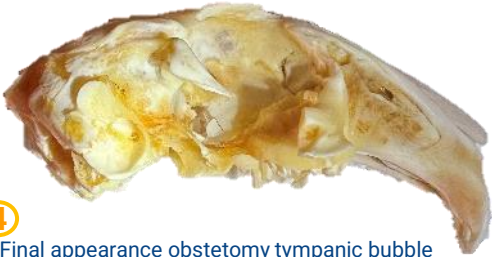

③

Complete osteotomy and osteoplasty with **ES007ST** and **ES010T** inserts.
Also useful for the removal of the abscess epithelium with dedicated soft tissue program

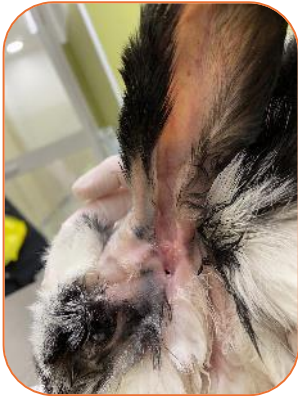

Final appearance removal of the ear canal and osteobullectomy

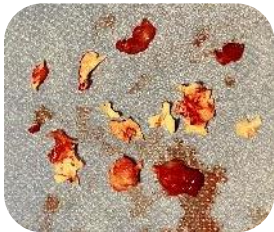

④

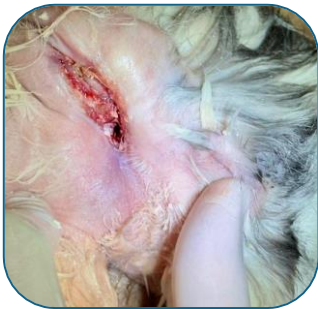Final appearance obstetomy tympanic bubble



Healing at 3 weeks



Pathological bone removed



POST

7

Video of the procedure. Scan the QR code!

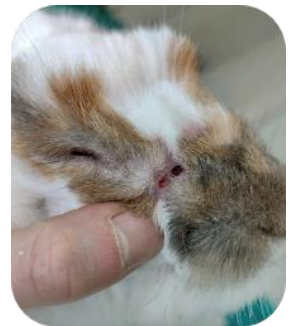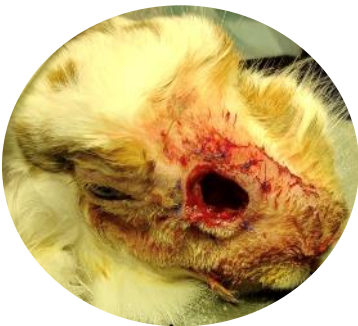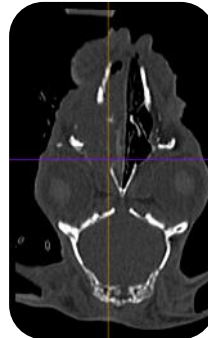


LATERAL/ MEDIAN RHINOTOMY

Chronic rhinitis is a relatively common condition, which can lead to life-threatening respiratory distress pictures as the Rabbit is a species forced to breathe nasally. The causes may be different, including: the origin of odontogenic, foreign bodies, traumatic, neoplasm or secondary to otitis media for bacterial spread through the Eustachian tube and nasopharyngeal meatus.

As with other pathologies with pus formation, it is often necessary to intervene surgically with lateral or dorsal **rhinotomy** when rhinitis involves the two nasal cavities.


We can easily perform the dorsal osteotomy with **ES007W1T** cutting insert, or **access through the thin lateral cribrosa facies** with **ES007ST** and **ES010T** obstetric inserts.



Fully healed
after three weeks

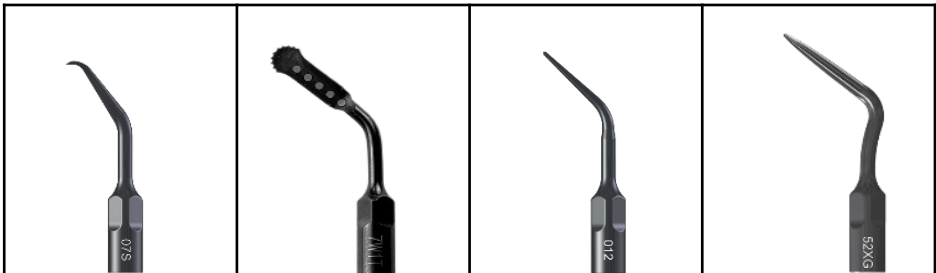DEDICATED INSERTS AND PARAMETERS

Surgery



Code	Code	Code	Code
ES009NT	ES010T	ES007LT	ES007RT

U	35	40	40	40
V	80	80	80	90
P	100	100	100	100
MAX POWER	50	50	50	50



Code	Code	Code	Code
ES007ST	ES007W1T	ES012T	ES052XGT

U	35	40	35	35
V	80	80	80	80
P	50	100	100	100
MAX POWER	50	50	40	40

U: Suggested power
V: Suggested vibration

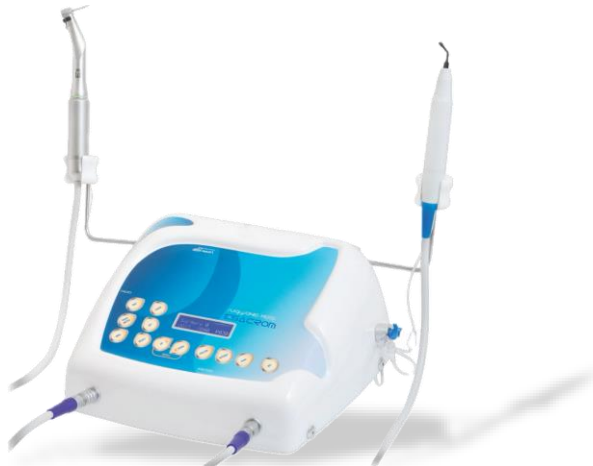P: Recommended pump rate
MAX POWER: Maximum power at which the insert can be used

DEDICATED INSERTS AND PARAMETERS

Medical

		
Code	Code	Code
ES015T	ES020XT	ES001T

U	20	20	20
V	40	40	40
P	100	100	100
MAX POWER	50	50	50



U: Suggested power
V: Suggested vibration
P: Recommended pump rate
MAX POWER: Maximum power at which the insert can be used

DR. FRANCESCO PAESANO

He graduated in 2013 from the **Faculty of Veterinary Medicine of the University of Pisa**, with an experimental thesis entitled "Partially Intravenous Anesthesia in the course of orthopedic procedures in wild avian species". Afterwards, he does internships and visits at zoological parks, wildlife recovery centers and clinics specializing in exotic animal medicine in Spain, Portugal, United Kingdom, Indonesia.



From 2013 to 2016 he worked in **Anesthesiology** and **Medicine and Surgery of Exotic Animals** at the Vet Hospital, Florence.

From 2016 to 2018 he worked on General Medicine of Small Animals, Medicine and Surgery of Exotic Animals and Odontostomatology at the Global United Veterinary Clinic in Abu Dhabi, United Arab Emirates.

Speaker at National and International Congresses: ICARE (International Congress Avian Reptile and Exotics mammals) in 2015 and 2019.

In 2022 he received the title of "General Practitioner Certificate in Small Animal Dentistry and Oral Surgery" from the International School of Veterinary Postgraduate Studies.

Since 2018 he has been dealing exclusively with **Odontostomatology** and **Surgery of Exotic Animals**, sectors of which he was responsible at the Clinica Veterinaria Borghesiana in Rome until September 2022.

He participates as a lecturer in the "Practical Course of Dentistry" Unisvet and the Course of Dentistry for veterinary technicians Unisvet.

His main fields of interest are Oncological Surgery and Maxillo Facial Trauma and Piezo Surgery.

Since October 2022 he has collaborated with **VetHospital**, with the clinics of the Florentine Cluster of VetPartnes Italy, and with many other structures in Tuscany.

From May 2023 collaborates with the Centro Toscano Recupero Avifauna Wildlife of Empoli.

DISCOVER OUR ULTRASONIC WORLD!

Follow us on     @esacromsrl

On our social profiles you can find continuous updates about #Esacrom education, join us to our courses and events to learn more!

For more info contact:

Esacrom srl

Via Zambrini 6/A-40026 IMOLA(BO)

TEL. +390542643527 FAX +390542482007 esacrom@esacrom.com